

## Tips and tricks how I...

remove an animal bone from the GI-tract

BSGIE Annual Meeting 17-9-2015:

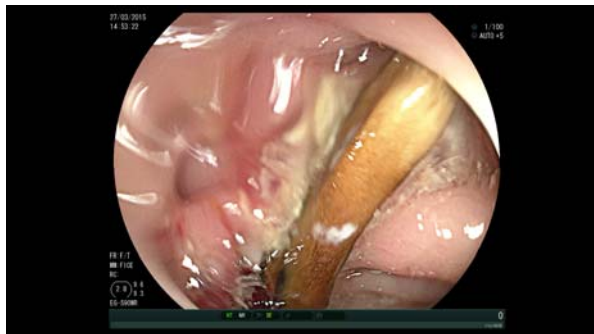I. Demedts

### Case

- ✦ F, 79y
- ✦ Asymptomatic
- ✦ Sent by GP for FU colonoscopy (2011: 3 tub adenoma's, LGD)

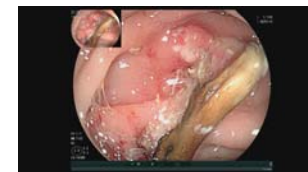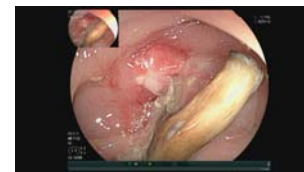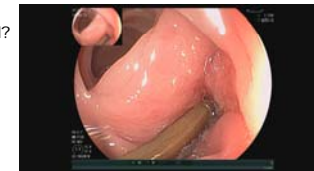### Colonoscopy

- ✦ 2 small polyps removed in right colon
- ✦ at 30 cm in sigmoid:



### Next step(s):

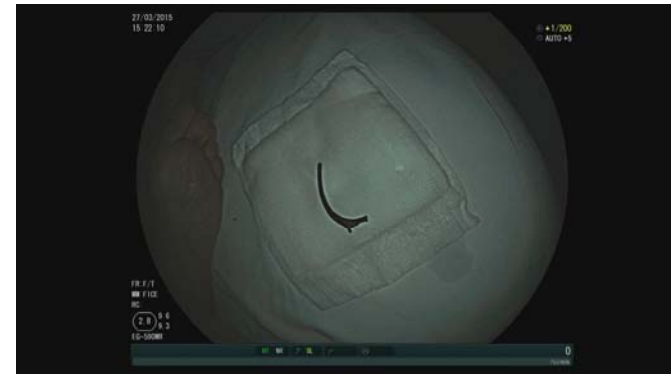- ✦ visualize complete object:
  - ✦ position in lumen
  - ✦ ends: loose, impacted, perforated?
  - ✦ is desimpaction possible?
  - ✦ depth of perforation?



### Next step(s):

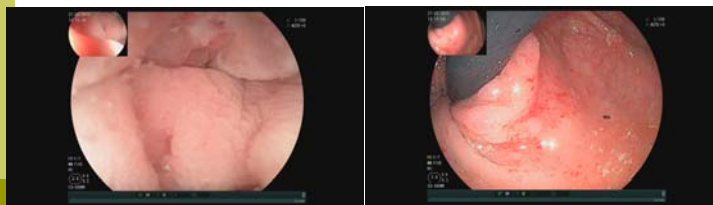
- remove object:
  - choose appropriate tool (snare, rat tooth or grasping forceps, biopsy forceps, Roth net,...) ⇒ crocodile forceps
  - if necessary, carefully desimpact (both) ends
    - ⇒ left side: laterally impacted, able to free: blunt extrusion
    - ⇒ right side: deep impacted end, able to free (with difficulty): jagged
  - for removal of long stiff objects: grasp close to/at the end, not in the middle
  - in general: grasp end closest to orifice
  - during retrieval: try and align longitudinal axis of object with lumen (not perpendicular or oblique)
    - ⇒ grasp jagged end, slowly retract
    - snagging of extrusion during anal sphincter passage

### Next step(s):



### Next step(s):

- after removal:
  - if in doubt: check for perforation or bleeding



⇒ 3d PO antibiotics

### Questions? Discussion?